

# Optic Nerve Morphology May Reveal Adverse Events During Prenatal and Perinatal Life—Digital Image Analysis

Ann Hellström, MD, PhD

*Department of Ophthalmology, Institute of Clinical Neuroscience and International Pediatric Growth Research Center, Department of Pediatrics, Sahlgrenska University Hospital/East, Göteborg, Sweden*

**Abstract.** *Objective:* To evaluate optic nerve morphology in children with various conditions caused by adverse events during prenatal and/or perinatal life and to investigate whether optic nerve morphology can reveal brain lesions associated with these conditions, as well as provide insight into the etiology and timing of the prenatal and perinatal damage. *Methods and patients:* A digital image analysis technique was used to analyze fundus photographs. One hundred healthy Swedish individuals of various ages from childhood to adolescence constituted a reference group. The following patient groups were chosen to represent various clinical conditions affecting the newborn or fetus at different stages of development: children born preterm (N = 39), children with fetal alcohol syndrome (FAS [N = 16]), children with periventricular leukomalacia (PVL [N = 17]), and children with septo-optic dysplasia (SOD [N = 6]). *Results:* Preterm children without known brain lesions demonstrated normal optic disk morphology but abnormal retinal vascular pattern; children born preterm with an acquired brain lesion late in gestation (PVL) demonstrated normal disk size with enlarged cups in addition to the abnormal vascular pattern. Children with prenatal alcohol exposure (FAS) had a subnormal optic disk area with increased tortuosity of both arteries and veins, whereas children born at term with an early acquired brain lesion (SOD) had a markedly reduced optic disk area with isolated tortuosity of the retinal veins. *Conclusions:* Evaluation of optic nerve morphology, by digital image analysis, demonstrated that differences in ocular fundus morphology were correlated with differences in etiology and timing of the adverse event occurring in prenatal and perinatal life. In addition, digital image analysis may be a helpful tool for understanding variations in optic nerve and retinal vessel morphology and their relationship with central nervous pathology. (*Surv Ophthalmol* 44 [Suppl 1]:S63–S73, 1999. © 1999 by Elsevier Science Inc. All rights reserved.)

**Key words.** children • digital image analysis • fetal alcohol syndrome • growth hormone insufficiency • magnetic resonance imaging • optic disk • optic nerve hypoplasia • periventricular leukomalacia • retinal vessels

Adverse events in the embryo, fetus, and newborn child may cause damage to the visual, central nervous, and vascular systems. This may lead to severe sequelae during childhood and in adult life, including visual impairment, mental retardation, and neurologic deficits.<sup>16,18,29,38,61</sup> Early identification and detailed diagnosis of prenatal and perinatal lesions of the brain and visual system are of great importance. If the disorders can be identified early, future quality of life may be enhanced by introduction of early rehabilitation.

Primarily, ultrasonography, computed tomography (CT), and magnetic resonance imaging (MRI) are used to examine brain morphology in the child. These methods have become very important in studying the outcome of prenatal and perinatal lesions in the brain. However, ultrasonography provides incomplete visualization of the brain, especially when the fontanels are closed. Furthermore, the applicability of CT and MRI in infants and small children is somewhat limited, because these techniques usually require sedation or general anes-

sia. In addition, availability, cost, and concerns over radiation exposure with CT may limit the use of these methods in clinical work.

The receptive area of the eye, i.e., the retina with its optic nerve, develops from the brain, with which it shares many characteristics. Unlike other parts of the nervous system, the optic nerve can be studied by direct inspection through the eye. Similarly, the retinal vessels are the only vessels that can be evaluated in detail without invasive techniques. Hence, the eye is an organ that allows studies of the central nervous system (CNS) and the vascular morphology by simple clinical methods. Such studies may be achieved by direct inspection (ophthalmoscopy) or, more objectively, by morphometric analysis of fundus photographs. Advances in computer hardware and software, as well as in photographic and imaging techniques, have allowed development of various image-processing methods, one of which has been used in the present study. On the basis of this standardized technique for objective analysis of optic nerve morphology, data have been presented for children with various clinical conditions affecting the newborn and child at different stages of development, including preterm birth, exposure to a teratogen (alcohol), and brain lesions acquired early and late in gestation.<sup>30,31,33,34,39</sup> In the current study, we reevaluated the optic nerve morphology in these children, using the same reference group and a new statistical approach, to investigate whether optic nerve morphology can reveal brain lesions associated with the conditions described above, as well as provide insight into the etiology and timing of the prenatal and perinatal damage.

## Methods

### DIGITAL IMAGE ANALYSIS

All fundus photographs were evaluated in a masked fashion by quantitative analysis of optic nerve morphology by means of a computer-assisted digital mapping system. A quality assessment of the measurement procedure for the digital image analyses is presented in Table 1. The reliability of the method demonstrates an overall (intraobserver, interobserver, and intergroup) variability in the measurements of optic disk area, expressed as standard deviation (SD), of 0.10 mm<sup>2</sup>.<sup>62</sup>

Fundus photographs were taken with a Nikon Retinapan 45-II or a Canon 60UV fundus camera, magnification factor set at  $\times 1.7$ . Only well-focused photographs, with the optic disk centered, were accepted. The original color transparency was projected simultaneously with the scanned black-and-white PC monitor image to facilitate definition of the different fundus structures.

The optic disk, cup, and peripapillary crescent areas were measured by marking their outlines with a cursor. The projected area was automatically calculated by the computer (Fig. 1). The optic disk was defined by the inner border surrounding the nerve tissue; care was taken not to include the white peripapillary scleral ring. The cup was defined by its contour, and the course of the vessels and the pallor of the cup facilitated its demarcation. The cup was easy to delineate when it appeared deep and had steep boundaries. When the cup appeared shallow and had sloping walls and indistinct margins, it was more difficult to delineate, and multiple photographs from slightly different views had to be evaluated. The neuroretinal rim area was obtained by subtraction of the cup area from the disk area.

The retinal vessels (arterioles and venules), referred to as arteries and veins, were measured by tracing the path length of each vessel from its origin on the optic disk to a reference circle with a radius of 3.0 mm from the geometric center of the optic disk. The indices of tortuosity for arteries and veins were defined as the path length of the vessel divided by the linear distance from the vessel origin to the reference circle. The number of vessel branching points (arteries and veins) within the reference circle was automatically calculated. Arteries were distinguished from veins by their smaller diameter and by their brighter appearance.

Magnification (M) was corrected with the formula of Bengtsson<sup>5</sup>:  $M = 1 - 0.017 G$ , where G represents the refraction. This method was chosen because measurements of corneal curvature require extensive patient cooperation, which is difficult to obtain in young children.

In children born preterm, correction for magnification could not be performed, because disturbed eye development is common. Thus, a flatter anterior

TABLE 1

*The Intraobserver and Interobserver Variability as Evaluated by Two Observers Measuring Six Photographs From Children With Fetal Alcohol Syndrome and Six Photographs From Healthy Controls*

	Variability Coefficient of Variation (%)	
	Intraobserver	Interobserver
Optic disk area (mm <sup>2</sup> )	2	2-4
Tortuosity of arteries (index)	1-2	2-8
Tortuosity of veins (index)	1	1-3

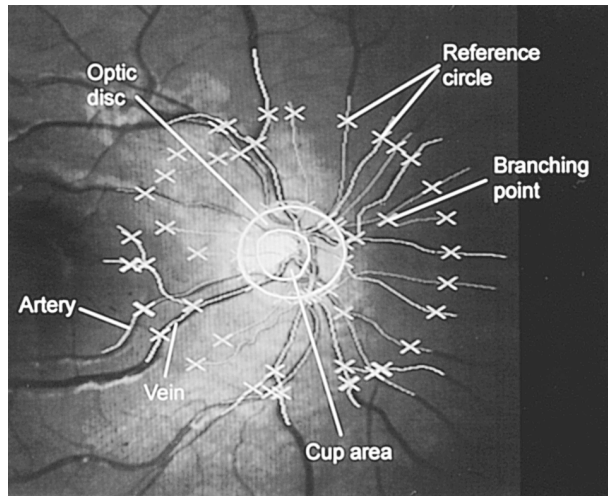


Fig. 1. Digital image analysis of a fundus photograph in an 8-year-old healthy boy.

chamber, a thicker and more spheroid lens, and a shorter axial length<sup>22,28,46</sup> probably cause the myopia commonly seen in these children. Consequently, the correction methods used in full-term children should not be applied to the eyes of preterm children.

Children with refraction values above +4 or below -4 diopters (D) were excluded from the analyses, as refraction values in these ranges might influence measurements of the ocular fundus structures.

Eye examination included an assessment of visual acuity, refraction (expressed as spherical equivalent) in cycloplegia, ophthalmoscopy, and fundus photography.

Cerebral imaging was performed with CT and/or MRI in children with periventricular leukomalacia (PVL). The localization and extent of brain tissue loss was estimated by the established CT and MRI criteria for PVL.<sup>23,24</sup> In children with optic nerve hypoplasia (ONH) and pituitary hormone insufficiency, cerebral imaging was performed with MRI.

Growth hormone (GH) status was estimated from values obtained during measurement of spontaneous 24-hour GH secretion and/or during an arginine-insulin tolerance test.<sup>2,6</sup> Growth hormone insufficiency was defined as a  $GH_{\max} < 32\text{mU/L}$ .

Prenatal, perinatal, and postnatal medical history was disclosed by interviewing the mothers of the children according to a standardized protocol regarding adverse events during pregnancy, to identify general disease, gynecologic bleeding, infections, and other complications of pregnancy, as well as smoking and alcohol or drug abuse. In addition, the maternity and delivery files were thoroughly checked regarding these factors.

## STATISTICAL METHODS

The mean value of the two eye measurements was calculated for each studied fundus structure. If the fundus photograph of one eye was of insufficient quality, only the contralateral eye was used. Reference centiles were obtained from the empiric distribution of the 100 children in the reference group. Possible associations between the studied variables were evaluated by the Spearman rank-order correlation coefficient.

The distributions of the measurements of the fundus variables were compared with the median of the reference values by means of the sign test. The probability of a randomly selected individual in one of the four groups having a smaller value than a randomly selected individual in the reference group was estimated by means of a modified Mann-Whitney test formula.

To avoid the mass significance effect and to obtain an overall significance level of 5%, the individual *p* values were corrected for multiple tests, according to Holm.<sup>35</sup>

## Patients

This study was approved by the Medical Ethics Committee at the University of Göteborg and the Karolinska Institute in Stockholm. Informed consent was obtained from the parents of each child and, if they were old enough, from the children.

## REFERENCE GROUP

One hundred healthy white Swedish children and adolescents between 3 and 19 years of age constituted the reference group. The children had no history of prenatal or perinatal morbidity, and only healthy children without congenital, chronic, or other serious disorders were included in the study. All children had a gestational age between 38 and 42 weeks and a normal (within  $\pm 2$  SD) body weight and height for their age at the time of birth and at the time of the eye examination. Visual acuity in the children ranged from 0.8 to 1.0 (median, 1.0) and refraction ranged from -1 to +1 D.

The measurements of optic disk size in the healthy children and adolescents were in accordance with the optic disk size found in most studies of adults.<sup>33</sup>

## STUDY GROUPS

### Preterm Birth

Thirty-nine preterm children (19 boys and 20 girls), with a mean age of 5 years (range, 3-9 years) and a median gestational age at birth of 29 weeks (range, 25-32 weeks) were selected for the study.<sup>31</sup>

Visual acuity (uncorrected) ranged from 0.15 to 1.0 (median, 0.65). Refraction ranged from  $-3$  to  $+4$  D.

Preterm birth carries a greatly increased risk of childhood morbidity, manifested, for example, by bronchopulmonary dysplasia, brain injury, and visual impairment.<sup>12,20,48</sup> Preterm infants are at high risk of developing retinopathy of prematurity, myopia, strabismus, and optic nerve abnormalities.<sup>27,42,44</sup>

### Periventricular Leukomalacia

Seventeen children with PVL (10 boys and seven girls) with a median age of 7 years (range, 5–18 years) and a median gestational age at birth of 29 weeks (range, 25–37 weeks) were selected for the study.<sup>39</sup> Visual acuity ranged from 0.05 to 1.0 (median, 0.4). Refraction ranged from  $-4$  to  $+4$  D.

The brain lesion caused by perinatal hypoxic-ischemic events in preterm children has a typical anatomic pattern known as PVL.<sup>4,17</sup> Periventricular leukomalacia affects the corticospinal tracts, causing spastic diplegia,<sup>43</sup> and/or the posterior visual pathways, causing visual impairment.<sup>38,52</sup>

### Fetal Alcohol Syndrome

Sixteen children with fetal alcohol syndrome (FAS) (nine boys and seven girls) with a median age of 7 years (range, 2–19 years) and a median gestational age at birth of 38 weeks (range, 27–42 weeks) were selected for the study.<sup>30</sup> Visual acuity ranged from 0.2 to 1.0 (median, 0.8). Refraction ranged from  $-2$  to  $+4$  D.

Maternal alcohol abuse during pregnancy may cause severe damage to the offspring, manifested by FAS.<sup>40</sup> The criteria for diagnosis of FAS were defined by Sokol and Clarren and include malformations, especially of the face, and prenatal and postnatal growth retardation, and psychomotor disturbances.<sup>57</sup> The frequency of FAS has been estimated to be 1 to 2 per 1,000 live births.<sup>19,50</sup>

### Optic Nerve Hypoplasia and Pituitary Hormone Insufficiency

Six children with ONH and pituitary hormone insufficiency (four girls and two boys) with a median age of 7.1 years (range, 2.8–13 years) and a median gestational age at birth of 38 weeks (range, 37–40 weeks) were selected for the study. Visual acuity ranged from no light perception to 0.6 (median, no light perception). Refraction ranged from  $-1$  to  $+1$  D. One child did not have fundus photography performed.

The association between ocular fundus abnormalities, midline brain lesions, and pituitary hormone insufficiencies has been well documented in septo-optic dysplasia.<sup>16,37,41</sup> A relationship between ONH and

isolated GH insufficiency, without detectable midline brain involvement, has been shown previously.<sup>10,58</sup>

## CONSIDERATIONS OF THE MATERIALS

Our study focuses on the effects of prenatal and perinatal adverse events, as reflected in the ocular fundus and CNS. Because reliable fundoscopic photographs are difficult to obtain in neonates and young children without general anesthesia, all fundoscopic analyses were based on examinations of children 2 years of age and older. To investigate whether detected fundus abnormalities could be caused by events occurring after the perinatal period, all medical files were reviewed and the parents of the children were interviewed. No evidence of any morbidity likely to have had an influence on ocular fundus morphology was revealed, other than among the children born preterm, where one child had had an episode of meningitis, one had had an acute pyelonephritic episode, and one child had had oxygen treatment for 2 years because of bronchopulmonary dysplasia.

On the basis of the available anamnestic and clinical information, it seems unlikely that the ocular fundus abnormalities were caused by events occurring after the perinatal period.

## Results

### OPTIC NERVE MORPHOLOGY

The various groups demonstrated differences in optic nerve morphology (Figs. 2 and 3) compared to the reference group, as follows. The preterm children demonstrated normal optic disk morphology. The children with PVL had large cups ( $P = 0.002$ ) in normal-sized disks and, consequently, small rim areas ( $P = 0.004$ ). The children with FAS had smaller optic disk areas ( $P = 0.002$ ), cup areas ( $P < 0.01$ ), and rim areas ( $P = 0.004$ ). The children with ONH and pituitary hormone insufficiency demonstrated markedly small optic disks ( $P = 0.03$ ) and neuroretinal rim areas ( $P = 0.03$ ).

The probability that a randomly selected individual in each of the study groups will have smaller optic disk, cup, or rim areas than a randomly selected individual from the reference group is given in Table 2.

### RETINAL VESSEL MORPHOLOGY

The probability that a randomly selected individual in each of the study groups will have different (higher or lower) values of the indices of tortuosity for arteries and veins and a lower number of vascular branching points than a randomly selected individual from the reference group is shown in Table 3.

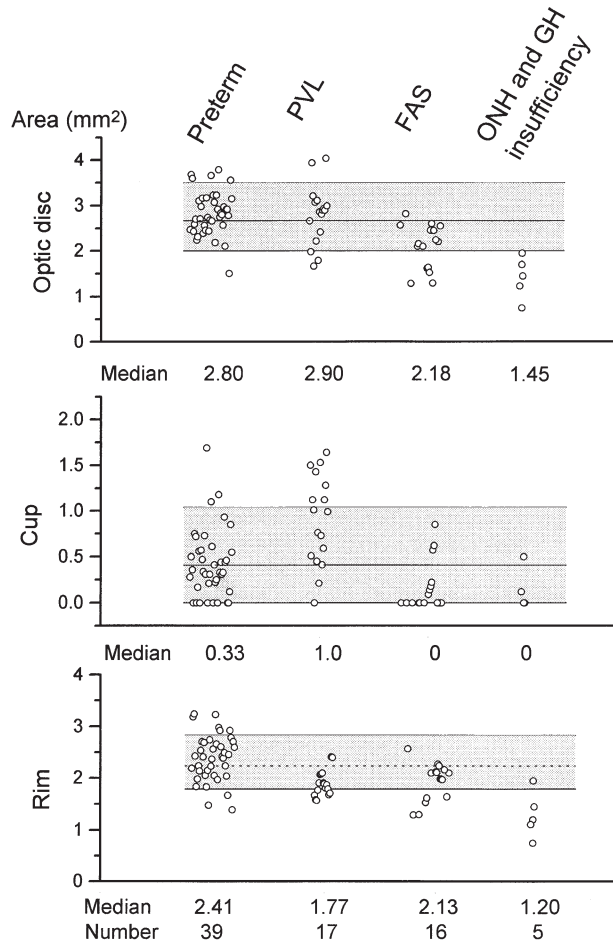


Fig. 2. Individual and median values for optic disk, cup, and neuroretinal rim areas in four groups of children. The shaded area depicts the fifth to the 95th percentile range, and the center line indicates the median for the healthy reference group.

The various groups demonstrated differences in retinal vessel morphology (Figs. 3 and 4) compared to the reference group, as follows. The preterm children had high indices of tortuosity for arteries ( $P < 0.0001$ ) and veins ( $P < 0.0001$ ) and few vascular branching points ( $P < 0.0001$ ). The children with PVL demonstrated tortuosity of the retinal arteries ( $P = 0.025$ ) and veins ( $P = 0.006$ ). Children with FAS had high indices of tortuosity of arteries ( $P = 0.04$ ) and veins ( $P = 0.002$ ) and few vascular branching points ( $P = 0.04$ ). Children with ONH and GH insufficiency had tortuous retinal veins ( $P = 0.016$ ) and a low number of vascular branching points ( $P = 0.03$ ).

There was no change in any of the studied fundus measurements with age or refraction, and no differences were found between boys and girls or right and left eyes. There was no correlation between the size of the optic disk and the vessel tortuosity in any of the groups studied.

## Discussion

Quantitative morphologic evaluation of the optic nerve and retinal vessels has for many years been a useful tool in the detection and follow-up of various disorders in adults. For example, it has contributed to our understanding of the underlying disease in various diagnoses in adults, e.g., diabetes, hypertension, and glaucoma. In children, however, optic nerve and retinal vessel morphology have traditionally been subjectively evaluated, and fundus morphology measurements have mainly been restricted to autopsy findings.<sup>54</sup>

To facilitate more objective evaluation of fundus photographs, we used a standardized technique for analysis of optic nerve morphology. We used a digital image analysis that was specifically designed for evaluation of both optic nerve and retinal vessel structures suspected to be influenced by prenatal and perinatal adverse events. To our knowledge, this cannot be achieved by other systems. The system was shown to be simple, accurate, reproducible, and relatively fast.<sup>62</sup> In addition, there appeared to be a good correlation between our method and other methods used for analyses of fundus structures.<sup>33</sup>

Clinical conditions representing various etiologies and affecting the fetus or newborn at different stages of development were selected to discover if etiology or timing of a lesion could be demonstrated in the optic nerve morphology.

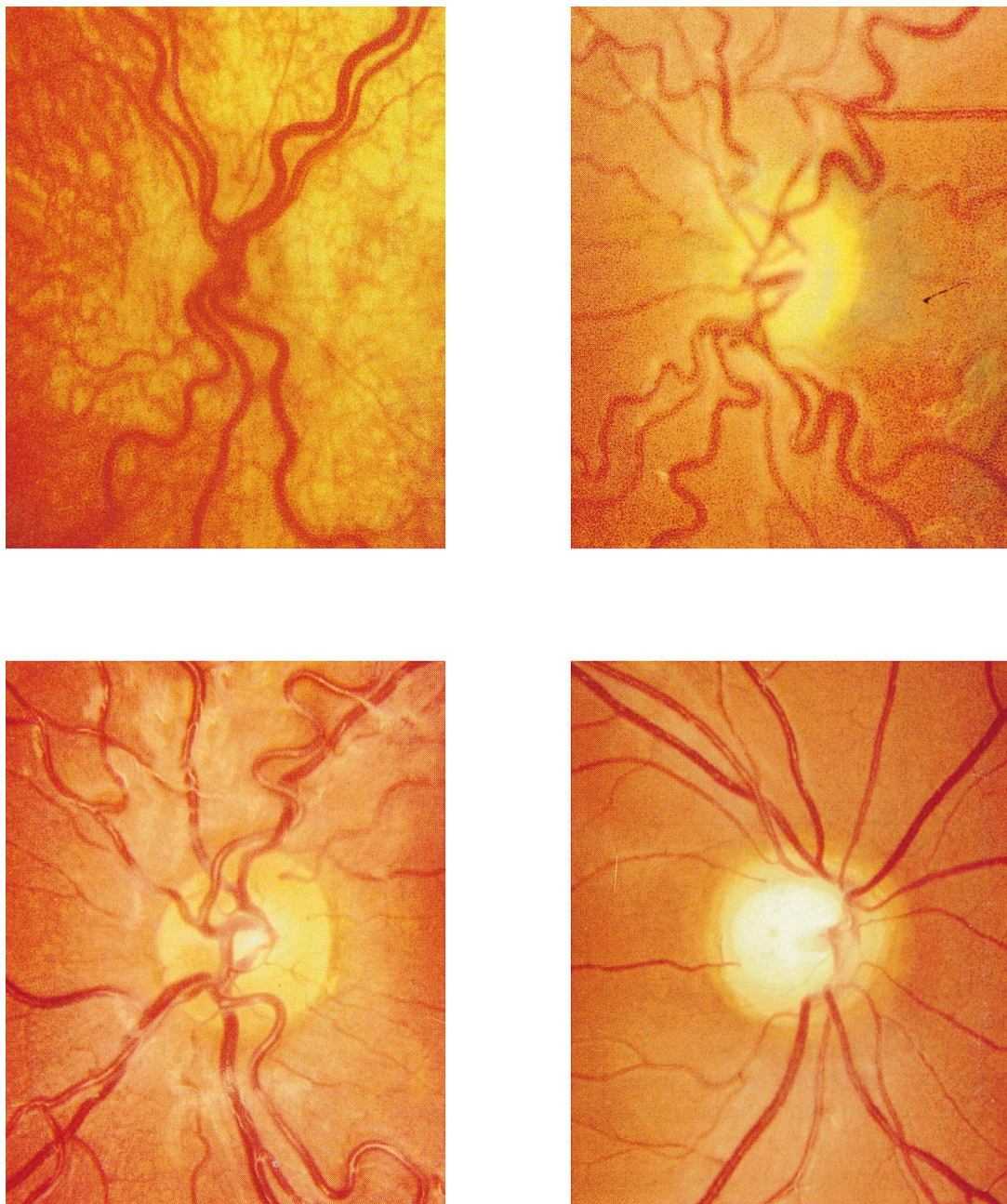
## ETIOLOGY

Differences in the optic nerve morphology and retinal vascular pattern were seen in patients based on the different etiologies of their clinical conditions.

### Preterm Birth

Preterm birth was associated with a markedly increased tortuosity of the retinal arteries (Figs. 3 and 4), as previously described by Fielder et al.<sup>21</sup> In addition, an increased tortuosity of the retinal veins was noted. Bracher discussed the mechanisms of abnormal retinal vascular tortuosity in newborn infants and suggested that hypoxia (perinatal distress) causes relaxation of the arteriolar muscles, resulting in elongation and abnormal tortuosity of the vessels.<sup>7</sup> A majority of the preterm children in our study suffered from perinatal distress, including poor oxygenation requiring oxygen treatment. It has been shown that fluctuations in oxygenation,<sup>56</sup> hypoxia,<sup>47</sup> and hyperoxygenation<sup>25</sup> may be associated with abnormal vascularity in the retina, i.e., retinopathy of prematurity. It thus seems reasonable to suggest that oxygen plays an important role in the development of the retinal vascular pattern noted in the children born preterm, although this is difficult to prove in





*Fig. 3.* Fundus photographs in four children with various clinical conditions affecting the newborn or fetus at different stages of development. *Top Left:* A 6-year-old boy with septo-optic dysplasia, very small optic disk, and tortuous veins. *Top Right:* A 13-year-old girl with fetal alcohol syndrome, small optic disk, and tortuous vessels. *Bottom Left:* A 7-year-old preterm girl with normal optic disk and tortuous vessels. *Bottom Right:* An 18-year-old boy with periventricular leukomalacia and large cup in normal-sized disk.

clinical studies. Chan-Ling and Stone demonstrated that retinal ganglion cells were able to survive hypoxia, while the astrocytes, involved in the formation of the glia limitans of the retinal vessels, degenerated and caused a failure of the blood-retinal barrier.<sup>13</sup> By decreasing the structural support for the retinal vessels, the reduction in the number

of astrocytes seen during hypoxia could be another cause of the vascular tortuosity noted in children born preterm.

The normal optic disk morphology found among the preterm children was surprising, as prematurity is associated with ONH,<sup>1,48</sup> which usually causes a small optic disk.

TABLE 2

*Probability of a Randomly Selected Individual in the Study Groups Having a Smaller Optic Disk, Cup, or Rim Area Than a Randomly Selected Individual From the Reference Group*

	Probability (%)			
	Children Born Preterm (N = 39)	Children With PVL (N = 17)	Children With FAS (N = 16)	Children With ONH and Pituitary Hormone Insufficiency (N = 5)
Optic disk area	40	41	81	99
Cup area	51	22	74	76
Rim area	38	82	71	97

PVL = periventricular leukomalacia; FAS = fetal alcohol syndrome; ONH = optic nerve hypoplasia.

However, children born preterm with an acquired brain lesion late in gestation (PVL) demonstrated large cups in normal-sized optic disks in addition to the tortuous retinal vessels (Figs. 2 and 3).<sup>39</sup> A secondary degeneration of ganglion cells and their fibers is likely to be the pathogenetic mechanism that results in this morphologic appearance, as the primary ischemic brain lesion in PVL causes axonal interruption in the posterior visual pathways. It may be speculated that this interruption causes retrograde transsynaptic degeneration across the lateral geniculate nucleus, resulting in a variant of optic nerve hypoplasia. A recent report by Uggetti et al supports this hypothesis by demonstrating degeneration of the lateral geniculate nucleus as a possible consequence of transsynaptic degeneration in an MRI study of six patients, four of whom had PVL.<sup>64</sup>

### Prenatal Alcohol Exposure

In children with prenatal alcohol exposure, different optic nerve morphology with a small optic disk in association with tortuous arteries and veins (Figs. 2, 3, and 4) characterized the ocular fundus appear-

ance. The results of an experimental study by Parson et al suggested that the smaller number of optic nerve axons noted in mice exposed to alcohol prenatally was caused by a defective trophic mechanism.<sup>51</sup> This defective stimulation of axons to survive, mediated through lack of growth factors, resulted in excessive axon loss at the time of normal apoptosis. It may be speculated that the ONH seen among the children with FAS might be caused by this mechanism. A clinical study on six children with FAS demonstrated that such children had plasma concentrations of insulin-like growth factor I (IGF-I) and IGF-binding protein 3 (IGFBP-3) in the lower normal range.<sup>32</sup> The study also indicated that there may be a defective trophic mechanism in children with FAS. Ashwell and Zhang demonstrated a reduction in the number of optic nerve axons and deficient myelination in mice exposed to alcohol prenatally.<sup>3</sup> The authors found no decrease in the number of neurons located in the lateral geniculate nucleus and suggested that the low number of axons was caused by direct retinal damage, rather than by secondary damage caused by a lesion in the lateral

TABLE 3

*Probability of a Randomly Selected Individual in the Study Groups Having Higher Indices of Tortuosity of Arteries or Veins or a Lower Number of Branching Points Than a Randomly Selected Individual From the Control Group*

Vessel Variable	Probability (%)			
	Children Born Preterm (N = 39)	Children With PVL (N = 17)	Children With FAS (N = 16)	Children With ONH and Pituitary Hormone Insufficiency (N = 5)
Tortuosity of arteries (index)*	79	63	72	19
Tortuosity of veins (index)*	69	58	68	80
Branching points (number) <sup>†</sup>	82	62	71	99

PVL = periventricular leukomalacia; FAS = fetal alcohol syndrome; ONH = optic nerve hypoplasia.

\*The probability of an individual having a higher value.

<sup>†</sup>The probability of an individual having a lower value.

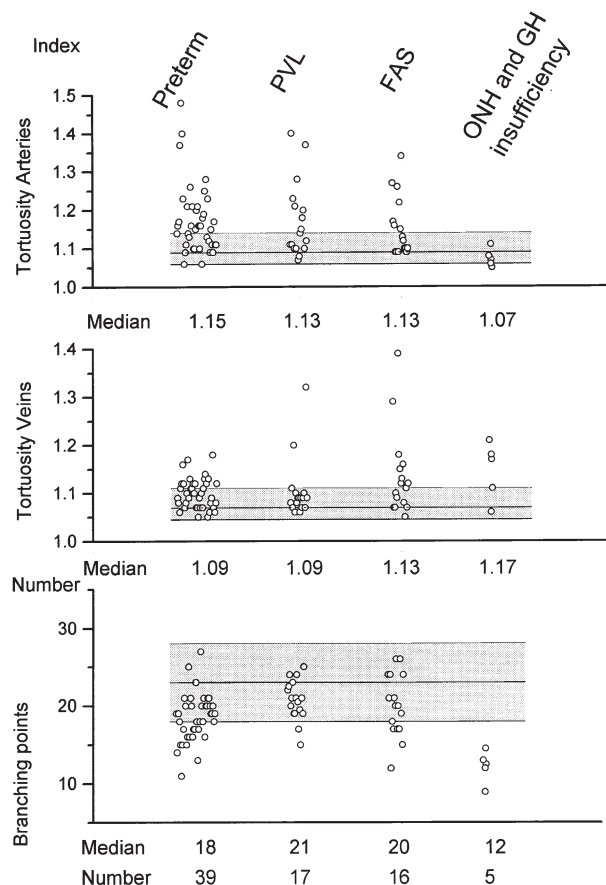


Fig. 4. Individual and median values for indices of tortuosity for arteries and veins and number of branching points in four groups of children. The shaded area depicts the fifth to the 95th percentile range, and the center line indicates the median for the healthy reference group.

geniculate nucleus. It thus seems possible that ONH in association with prenatal alcohol exposure may be mediated by several mechanisms, e.g., transsynaptic degeneration, insufficient growth factors, deficient astrocytes and oligodendrocytes, depletion of precursors of the retinal ganglion cells (discussed by Ashwell and Zhang,<sup>3</sup> but not yet demonstrated), or other unknown factors. Consequently, it seems reasonable to assume that the adverse effects of alcohol on the embryo and fetus are multifactorial and are influenced by factors such as timing of exposure, dose, and genetic predisposition.

#### Optic Nerve Hypoplasia and Pituitary Hormone Insufficiency

Children with an early acquired brain lesion (ONH and pituitary hormone insufficiency) had a specific ocular fundus appearance with a markedly small optic disk associated with isolated tortuosity

of the retinal veins (Figs. 2, 3, and 4).<sup>34</sup> An explanation for this morphologic appearance might be that a preexisting midline lesion in the pituitary region disturbs or prevents the outgrowing axons from the retina to travel to the posterior parts of the brain and form appropriate connections at their target site, i.e., the visual cortex, thereby causing secondary degeneration of the axons.<sup>8,36</sup> Such a mechanical hypothesis is supported by the findings of Taylor, who demonstrated ONH in patients with congenital suprasellar tumors,<sup>63</sup> and by the findings of lesions in the pituitary region in our study (unpublished data).

#### TIMING OF INSULT

The extent of damage caused by a lesion to the developing brain is influenced more by the stage of brain maturation at the time of the insult than by the insult per se.<sup>26,45</sup> Consequently, the same adverse event may result in various morphologic manifestations, depending on the timing of the lesion.<sup>55</sup> Because the optic nerve consists of an extension of the brain tissue, it seems logical to assume that the same reasoning applies for the optic nerve as for the brain. Our study showed that ONH might have a considerable morphologic variability in conditions occurring at different times during prenatal and/or perinatal life. It thus seems possible that the timing of the lesion might be one factor explaining the varying optic nerve morphology noted among these children.

The six children with ONH and pituitary hormone insufficiency had midline brain lesions, i.e., agenesis of the septum pellucidum, and lesions in the hypothalamopituitary region (unpublished data), which indicates an adverse event before the end of the first trimester.<sup>49</sup> Such an insult, involving the visual pathways during this developmental phase, seems to cause extensive damage to the retinal ganglion cells, i.e., the size of the optic disk was markedly subnormal, there were few and narrow retinal arteries, and there was marked tortuosity of the retinal veins. These morphologic abnormalities indicate a markedly reduced number of ganglion cells.

Alcohol is a teratogen that may exert its effects on the CNS throughout the entire period of gestation.<sup>14</sup> It may cause structural changes in the brain early during development, e.g., agenesis of the corpus callosum,<sup>53</sup> and later in fetal life, e.g., migration disturbances.<sup>15</sup> Optic nerve hypoplasia in association with FAS is most likely a result of an exposure to alcohol at any time from the beginning of embryonic life to later parts of fetal life, as shown in experimental studies.<sup>3,51</sup>

In the fully developed eye, the optic disk and nerve are surrounded by the relatively firm sup-



porting tissues of the sclera, pia mater, dura mater, and the lamina cribrosa, and the nervous tissue fills out the space surrounded by the supportive structures. A lesion that causes a reduction of the total number of retinal ganglion cells before the supportive tissues are fully developed may result in a small disk, because the supportive structures may still be able to adapt to the subnormal size of the nervous tissue of the optic disk/nerve, e.g., septo-optic dysplasia. Such adaptations may also occur in ONH with small disks, as are seen in children with PVL in whom MRI has demonstrated brain lesions corresponding to an insult in the second trimester.<sup>39</sup> The large cups in normal-sized disks observed in the majority of children with PVL were associated with brain lesions corresponding to insults in the third trimester. In the third trimester, the surrounding structures of the optic disk have become more rigid, and an adaptation to the smaller number of ganglion cells in the optic disk is unlikely. A lesion affecting the visual pathways in this developmental phase seems to result in a normal-sized disk with large cups and, consequently, a small rim area.

#### ASSOCIATIONS WITH OTHER BRAIN LESIONS

A number of associations between abnormalities of the optic nerve morphology and abnormalities of the CNS were found in our study.

The finding of large cups in normal-sized disks in children with PVL indicates that a large cup in a preterm child should raise the suspicion of associated damage in the posterior visual pathways.<sup>39</sup> This type of periventricular lesion is associated with impaired visual perception and cognitive problems<sup>38</sup> that may require extensive rehabilitation and support during childhood. Consequently, recognition of these morphologic patterns of the ocular fundus and knowledge about their association with this specific brain lesion are of great clinical importance.

A small disk and tortuous retinal vessels in a full-term (or preterm) child might indicate prenatal alcohol exposure,<sup>30</sup> which in a majority of cases is associated with brain lesions.<sup>59,60</sup> Children with FAS have extensive educational and social problems.<sup>61</sup> The clinical symptoms of FAS may be difficult to evaluate, and, because a large proportion of these children have ocular problems, the ophthalmologist plays an important role in recognizing the syndrome. A correct diagnosis is a prerequisite for better understanding and improved support of these often undiagnosed children.

A markedly small disk with retinal venous tortuosity may indicate the presence of midline brain lesions and associated pituitary hormone insuffi-

ciencies.<sup>11,34</sup> In children with pituitary insufficiencies and optic nerve anomalies, one of the most striking symptoms in early infancy is visual impairment. Therefore, these children are commonly referred to an ophthalmologist. Failure to recognize the morphologic fundus pattern, or unawareness of its potential association with midline brain damage and hormone insufficiency, may delay the diagnosis and expose the child to an increased risk of developmental delay, adrenal crisis, and even sudden death.<sup>9</sup>

In conclusion, it has been shown that quantitative evaluation of optic nerve morphology is a helpful contributory tool in the understanding of variations in optic nerve and retinal vessel morphology and their relationship with CNS pathology in the children studied.

The importance of quantifying the optic nerve morphology should be stressed, because the variations in optic nerve morphology that were seen in the different groups studied were most likely attributable to differences in etiology and timing of the lesions. Knowledge of the optic nerve morphology in children with various clinical conditions is incomplete, and additional research is needed to further explore this field. However, the results of our study clearly indicate the importance of evaluating optic nerve morphology as a platform for basic scientific studies and future clinical work.

#### References

1. Acers TE: Optic nerve hypoplasia: septo-optic-pituitary dysplasia syndrome. *Trans Am Ophthalmol Soc* 79:425-457, 1981
2. Albertsson-Wikland K, Rosberg S, Karlberg J, Groth T: Analysis of 24-hour growth hormone profiles in healthy boys and girls of normal stature: relation to puberty. *J Clin Endocrinol Metab* 78:1195-1201, 1994
3. Ashwell KW, Zhang LL: Optic nerve hypoplasia in an acute exposure model of the fetal alcohol syndrome. *Neurotoxicol Teratol* 16:161-167, 1994
4. Banker B, Larroche JC: Periventricular leukomalacia of infancy. *Arch Neurol* 7:32-56, 1962
5. Bengtsson B: The variation and covariation of cup and disk diameters. *Acta Ophthalmol* 54:804-818, 1976
6. Boguszewski M, Rosberg S, Albertsson-Wikland K: Spontaneous 24-hour growth hormone profiles in prepubertal small for gestational age children. *J Clin Endocrinol Metab* 80:2599-2606, 1995
7. Bracher D: Changes in peripapillary tortuosity of the central retinal arteries in newborns: a phenomenon whose underlying mechanisms need clarification. *Graefes Arch Clin Exp Ophthalmol* 218:211-217, 1982
8. Brodsky MC: Septo-optic dysplasia: a reappraisal. *Semin Ophthalmol* 6:227-232, 1991
9. Brodsky MC, Conte FA, Taylor D, et al: Sudden death in septo-optic dysplasia: report of 5 cases. *Arch Ophthalmol* 115:66-70, 1997
10. Brodsky MC, Glasier CM: Optic nerve hypoplasia: clinical significance of associated central nervous system abnormalities on magnetic resonance imaging. *Arch Ophthalmol* 111:66-74, 1993
11. Brodsky MC, Hoyt WF, Creig CS, et al: Atypical retinoblastoma.

- dal coloboma in patients with dysplastic optic discs and transsphenoidal encephalocele. *Arch Ophthalmol* 113:624-628, 1995
12. Burke JP, O'Keefe M, Bowell R: Optic nerve hypoplasia, encephalopathy, and neurodevelopmental handicap. *Br J Ophthalmol* 75:236-239, 1991
  13. Chan-Ling T, Stone J: Degeneration of astrocytes in feline retinopathy of prematurity causes failure of the blood-retinal barrier. *Invest Ophthalmol Vis Sci* 33:2148-2159, 1992
  14. Clarren SK, Alvord EC Jr, Sumi SM, et al: Brain malformations related to prenatal exposure to ethanol. *J Pediatr* 92: 64-67, 1978
  15. Clarren SK, Astley SJ: Pregnancy outcomes after weekly oral administration of ethanol during gestation in the pig-tailed macaque: comparing early gestational exposure to full gestational exposure. *Teratology* 45:1-9, 1992
  16. De Morsier G: Etudes sur les Dysraphies crânio-encéphaliques. III. Agénésie du septum lucidum avec malformation du tractus optique: la dysplasie septo-optique. *Schweiz Arch Neurol Neurochir Psychiatr* 77:267-292, 1956
  17. DeReuck J, Chattha AS, Richardson EP Jr: Pathogenesis and evolution of periventricular leukomalacia in infancy. *Arch Neurol* 27:229-236, 1972
  18. de Vries LS, Dubowitz LM, Dubowitz V, et al: Predictive value of cranial ultrasound in the newborn baby: a reappraisal. *Lancet* 2:137-140, 1985
  19. Dehaene P, Crepin G, Delahousse G, et al: Aspects épidémiologiques du syndrome d'alcoolisme fœtal. *Nouv Presse Med* 10:2639-2643, 1981
  20. Dowdeswell HJ, Slater AM, Broomhall J, Tripp J: Visual deficits in children born at less than 32 weeks gestation with and without major ocular pathology and cerebral damage. *Br J Ophthalmol* 79:447-452, 1995
  21. Fielder AR, Shaw DE, Robinson J, Ng YK: Natural history of retinopathy of prematurity: a prospective study. *Eye* 6:233-242, 1992
  22. Fledelius HC: Pre-term delivery and the growth of the eye: an oculometric study of eye size around term-line. *Acta Ophthalmol Suppl* 204:10-15, 1992
  23. Flodmark O, Lupton B, Li D, et al: MR imaging of periventricular leukomalacia in childhood. *AJR Am J Roentgenol* 152:583-590, 1989
  24. Flodmark O, Roland EH, Hill A, Whitfield MF: Periventricular leukomalacia: radiologic diagnosis. *Radiology* 162:119-124, 1987
  25. Flynn JT, Bancalari E, Snyder ES, et al: A cohort study of transcutaneous oxygen tension and the incidence and severity of retinopathy of prematurity [see comments]. *N Engl J Med* 326:1050-1054, 1992
  26. Friede RL: *Development neuropathology*, 2nd ed. New York, Springer-Verlag, 1989, pp 21-25
  27. Gallo JE, Lennerstrand G: A population-based study of ocular abnormalities in premature children aged 5 to 10 years. *Am J Ophthalmol* 111:539-547, 1991
  28. Gordon RA, Donzis PB: Refractive development of the human eye. *Arch Ophthalmol* 103:785-789, 1985
  29. Hagberg B, Hagberg G, Olow I, van Wendt L: The changing panorama of cerebral palsy in Sweden, VII: prevalence and origin in the birth year period 1987-90. *Acta Paediatr* 85: 954-960, 1996
  30. Hellstrom A, Chen Y, Stromland K: Fundus morphology assessed by digital image analysis in children with fetal alcohol syndrome. *J Pediatr Ophthalmol Strabismus* 1:17-23, 1997
  31. Hellstrom A, Hard A-L, Chen Y, et al: Ocular fundus morphology in preterm children: Influence of gestational age, birth size, perinatal morbidity and postnatal growth. *Invest Ophthalmol Vis Sci* 38:1184-1192, 1997
  32. Hellstrom A, Jansson C, Boguszewski M, et al: Growth hormone status in six children with fetal alcohol syndrome [see comments]. *Acta Paediatr* 85:1456-1462, 1996
  33. Hellstrom A, Svensson E: Optic disc size and retinal vessel characteristics in healthy children. *Acta Ophthalmol Scand* 76:260-267, 1998
  34. Hellstrom A, Wiklund L-M, Svensson E, et al: Optic nerve hypoplasia with isolated tortuosity of the retinal veins—a marker of endocrinopathy. *Arch Ophthalmol* (In press)
  35. Holm S: A simple sequentially rejective multiple test procedure. *Scand J Statist* 6:65-70, 1979
  36. Hoyt CS, Good WV: Do we really understand the difference between optic nerve hypoplasia and atrophy? *Eye* 6:201-204, 1992
  37. Hoyt WF, Kaplan SL, Grumbach MM, Glaser JS: Septo-optic dysplasia and pituitary dwarfism. *Lancet* 1:893-894, 1970
  38. Jacobson L, Ek U, Fernell E, et al: Visual impairment in preterm children with periventricular leukomalacia—visual, cognitive and neuropaediatric characteristics related to cerebral imaging. *Dev Med Child Neurol* 38:724-735, 1996
  39. Jacobson L, Hellstrom A, Flodmark O: Large cups in normal-sized optic discs: a variant of optic nerve hypoplasia in children with periventricular leukomalacia [see comments]. *Arch Ophthalmol* 115:1263-1269, 1997
  40. Jones KL, Smith DW: Recognition of the fetal alcohol syndrome in early infancy. *Lancet* 2:999-1001, 1973
  41. Kaplan SL, Grumbach MM, Hoyt WF: A syndrome of hypopituitary hypoplasia of optic nerve and malformation of prosencephalon: report of 6 patients. *Pediatr Res* 4:480, 1970
  42. Keith CG, Kitchen WH: Ocular morbidity in infants of very low birth weight. *Br J Ophthalmol* 67:302-305, 1983
  43. Krageloh-Mann I, Petersen D, Hagberg G, et al: Bilateral spastic cerebral palsy—MRI pathology and origin: analysis from a representative series of 56 cases [see comments]. *Dev Med Child Neurol* 37:379-397, 1995
  44. Kushner BJ: Long-term follow-up of regressed retinopathy of prematurity. *Birth Defects* 24:193-199, 1988
  45. Larroche JC: Fetal encephalopathies of circulatory origin. *Biol Neonate* 50:61-74, 1986
  46. Laws DE, Haslett R, Ashby D, et al: Axial length biometry in infants with retinopathy of prematurity. *Eye* 8:427-430, 1994
  47. Lucey JF, Horbar JD, Onishi MJ: Cerebral and retinal hypoperfusion as possible cause of retrolental fibroplasia. *Pediatr Res* 15:670, 1981
  48. Margalith D, Jan JE, McCormick AQ, et al: Clinical spectrum of congenital optic nerve hypoplasia: review of 51 patients. *Dev Med Child Neurol* 26:311-322, 1984
  49. O'Rahilly R, Müller F: The endocrine system, in: O'Rahilly R, Müller F. *Human Embryology and Teratology*. New York, Wiley-Liss Inc, 1996, ed 2, pp 317-327
  50. Olegard R, Sabel KG, Aronsson M, et al: Effects on the child of alcohol abuse during pregnancy: retrospective and prospective studies. *Acta Paediatr Scand Suppl* 275:112-121, 1979
  51. Parson SH, Dhillon B, Findlater GS, Kaufman MH: Optic nerve hypoplasia in the fetal alcohol syndrome: a mouse model. *J Anat* 186:313-320, 1995
  52. Pinto-Martin JA, Dobson V, Cnaan A, et al: Vision outcome at age 2 years in a low birth weight population. *Pediatr Neurol* 14:281-287, 1996
  53. Riley EP, Mattson SN, Sowell ER, et al: Abnormalities of the corpus callosum in children prenatally exposed to alcohol. *Alcohol Clin Exp Res* 19:1198-1202, 1995
  54. Rimmer S, Keating C, Chou T, et al: Growth of the human optic disk and nerve during gestation, childhood, and early adulthood. *Am J Ophthalmol* 116:748-753, 1993
  55. Rorke LB: *Pathology of Perinatal Brain Injury*. New York, Raven Press, 1982, pp 4, 45
  56. Saito Y, Omoto T, Cho Y, et al: The progression of retinopathy of prematurity and fluctuation in blood gas tension. *Graefes Arch Clin Exp Ophthalmol* 231:151-156, 1993
  57. Sokol RJ, Clarren SK: Guidelines for use of terminology describing the impact of prenatal alcohol on the offspring. *Clin Exp Res* 13:597-598, 1989
  58. Stanhope R, Preece MA, Brook CG: Hypoplastic optic nerves and pituitary dysfunction: spectrum of anatomical and endocrine abnormalities. *Arch Dis Child* 59:111-114, 1984
  59. Steinhausen HC, Willms J, Spohr HL: Long-term psychopathological and cognitive outcome of children with fetal al-

- cohol syndrome. *J Am Acad Child Adolesc Psychiatry* 35: 990–994, 1993
60. Streissguth AP, Barr HM, Sampson PD: Moderate prenatal alcohol exposure: effects on child IQ and learning problems at age 7.5 years. *Alcohol Clin Exp Res* 14:662–669, 1990
  61. Stromland K, Hellstrom A: Fetal alcohol syndrome—an ophthalmological and socioeducational prospective study. *Pediatrics* 97:845–850, 1996
  62. Stromland K, Hellstrom A, Gustavsson T: Morphometry of the optic nerve and retinal vessels in children by computer-assisted image analysis of fundus photographs. *Graefes Arch Clin Exp Ophthalmol* 233:150–153, 1995
  63. Taylor D: Congenital tumours of the anterior visual system with dysplasia of the optic discs. *Br J Ophthalmol* 66:455–463, 1982
  64. Uggetti C, Egitto MG, Fazzi E, et al: Transsynaptic degeneration of lateral geniculate bodies in blind children: in vivo MR demonstration. *Am J Neuroradiol* 18:233–238, 1997

---

The author is grateful for the constructive criticism of Prof. Kerstin Albertsson-Wikland, Prof. Kerstin Strömmland, Assoc. Prof. Elisabeth Svensson, and Assoc. Prof. Lars Frisén, as well as for financial support from De Blindas Vänner, Kronprinsessan Margaretas Arbetsnämnd för synskadade, and from Knut och Alice Wallenbergs Stiftelse.

The author has no proprietary interest in any product or concept discussed in this article.

Reprint address: Ann Hellström, MD, PhD, Section of Pediatric Ophthalmology, Sahlgrenska University Hospital/Östra, S-416 85 Göteborg, Sweden.